

# Visuospatial Memory in Healthy Elderly, AD and MCI: A Review

Tina Iachini<sup>\*1</sup>, Alessandro Iavarone<sup>2</sup>, Vincenzo Paolo Senese<sup>1</sup>, Francesco Ruotolo<sup>1</sup> and Gennaro Ruggiero<sup>1</sup>

<sup>1</sup>Department of Psychology, Second University of Naples, Italy

<sup>2</sup>Unit of Neurology ASL Naples 1 CTO, Italy

**Abstract:** In the literature it is commonly reported that several spatial abilities decline with normal aging, even though such a decline is not uniform. So far, it is not yet clear which spatial components present a normal age-related decline, which ones are preserved and at what point the deficit is so severe to represent an index of mild cognitive impairment (MCI) or a symptom of potential degenerative progression as in the early-stage Alzheimer's disease (AD). In particular, AD (from early onset) is characterised by impairments in constructive abilities, visuospatial intelligence, spatial short-term memory deficits, and disorders of spatial orientation (topographical disorientation). MCI indicates a condition, generally affecting older individuals, characterized by cognitive deficits including memory and/or non memory impairments and at high risk of progression to dementia. Three MCI subgroups have been distinguished and a very high risk of developing AD is associated to the amnesic MCI subtypes. Further, recent studies have suggested that the allocentric component of spatial memory might be taken as predictor of AD from MCI. Given the frequency of visuospatial deficits in early-stage AD, evaluation of visuospatial processes is a promising approach to find predictive markers of AD. Here we report a review of the literature exploring specific visuospatial components in normal aging, MCI, and AD. In this way we could shed some light on the role of these components in the progression from MCI to AD and pave the way for future studies.

**Keywords:** Normal aging, MCI, AD, visuospatial abilities, visuospatial memory, predictors.

## INTRODUCTION

Over the past decades, interest has been growing in determining the predictors of Alzheimer's disease (AD). Accordingly, research efforts have been devoted to early pre-dementia stages of AD when subjects typically present with memory complaints and show deficits on neuropsychological tests, but do not fulfil the clinical criteria for dementia because of the isolated nature of the cognitive deficits and the preservation of everyday abilities. Although a number of different labels have been applied to patients in this prodromal state [1], there is now wide acceptance of the term MCI, i.e. Mild Cognitive Impairment. Many patients with MCI may progress to AD in few years [2]. Typically, performance of MCI patients on standard psychometric tests is in between that of healthy elderly and AD patients. MCI patients can be difficult to differentiate from individuals with normal age-related cognitive decline or mild memory loss associated with depression. The possibility of framing a memory deficit as normal or pathological for age and education standards is therefore crucial to differ the natural course of aged cognition from MCI and, possibly, to predict future onset of AD.

A long-standing literature has addressed the question of which deficits can be taken as early predictors of AD. So far, the greatest attention has been paid to verbally-mediated memory disorders, specifically episodic and semantic memory that are traditionally considered the earliest and deepest deficits [3]. Visuospatial deficits, even in early

stages of AD, have long been recognized but have been studied much less closely [4,5]. Disorders of spatial orientation (topographical disorientation) are considered an early symptom of dementia [6], and often attributed to the hippocampal damage [7]. Some authors have suggested that visuospatial deficits can precede typical memory impairments in very prodromal phases [8,9]. Therefore, consensus is still lacking on the staging of the cognitive deficits that follow, precede, or coexist with memory impairments during the progression of the disease, particularly early in its course. Here we discuss some studies about visuospatial memory in AD and MCI patients. Definition and taxonomy of MCI patients and data about rates of conversion to AD are also provided. We do not focus on Topographical Disorientation (extensive reviews are already available [10]). It is not our aim to provide a comprehensive review of all studies dealing with spatial processes in MCI and AD (if ever possible) but to analyze critically the theoretical constructs measured and the psychometric tasks used in comparison with models and paradigms of cognitive psychology. In particular, we will try to clarify what is "spatial" in visuospatial processes and to analyze the cognitive processing components of frequently poorly specified tasks. In doing so, the hypothesis that spatial memory deficits may represent an early sign of degenerative dementia will be discussed and findings suggesting this possibility will be presented. Further, a brief overview of visuospatial abilities in healthy elderly people will be sketched in order to provide a baseline of normal functioning of spatial cognition with aging. We wish to emphasize that the research efforts to find out early predictors of AD would benefit from a closer cross-talk between clinical approaches and cognitive psychology.

\*Address correspondence to this author at the Department of Psychology, Second University of Naples, Via Vivaldi, 43, 81100, Caserta, Italy; Fax: +39 0823 323000; Tel: +39 0823 274789; E-mail: santa.iachini@unina2.it

**Table 1. Subtypes of Mild Cognitive Impairment (MCI) classified on the Basis of Presumed Aetiology. Adaptation from Petersen (2004) [13]**

Subtypes of Mild Cognitive Impairment	Aetiology		
	Degenerative	Vascular	Psychiatric
<i>Amnesic</i>	AD	-	Depression
<i>Multiple-domain with amnesia</i>	AD	VaD	Depression
<i>Multiple-domain without amnesia</i>	DLB	VaD	-
<i>Single non-memory domain</i>	FTD - DLB	-	-

AD = Alzheimer's disease; DLB = Dementia with Lewy Bodies; FTD = Frontotemporal Dementia; VaD = Vascular dementia.

## 1. METHOD AND MATERIALS

The review of the literature was conducted using a systematic method. The search was carried out in PubMed, a free digital archive of biomedical and life sciences journal literature, and CSA Illumina, a digital archive of literature comprising social science, technology, and medicine databases.

Relevant articles were identified through searches using the terms Alzheimer and Mild Cognitive Impairment with no restriction as to year. This produced 2385 articles and 4418 articles, respectively from PubMed and CSA Illumina. In order to refine the research, articles were further narrowed to those that contained the word visuospatial. The final result was 709 articles. Starting from the abstracts, we selected articles tapping specifically visuospatial abilities and considering humans. This led to a selection of about 40 articles. Additional information from relevant publications were used for the background information about definitions and taxonomies of MCI and spatial memory in normal aging.

## 2. MCI BETWEEN NORMAL AGING AND AD

Healthy elderly people between 60 and 80 years should reveal a decline in the efficiency of cognitive functions of 10%, and this change should be mainly concerned with reasoning, learning, recalling events and experiences [11]. The detection of a prodementia state from normal aging is burdened by the fact that MCI lies subtly between normal aging and AD [12-17]. Indeed, the typical prodromal sign of onset of dementia, i.e. memory loss, is also associated with other clinical conditions such as depression, anxiety, learning disability, physical illness and so forth that should be excluded from investigations to ascertain the risk of developing dementia. As illustrated in Table 1 (adapted from [13]), different subtypes of mild cognitive impairments can be characterized by several damaged domains and by diverse etiology.

Starting from the definition proposed by Kral [14] of normal aging as "benign senescent forgetfulness" state, it was later introduced a further distinction between "age-associated memory impairment" which is benign (corresponding to at least 1 SD below the scores of young people) and a more severe decline (corresponding to at least 1 or 2 SDs below the scores of a normal sample) [15]. The concept of MCI was initially introduced by Flicker and

colleagues [16] and the Mayo Clinic group [17] to fill the gap between cognitive changes associated with normal aging and those associated with dementia. Officially, the classification of prodementia states as MCI appeared in the ICD-10 and DSM-IV manuals.

### 2.1. Taxonomy of Mild Cognitive Impairment and Rate of Conversion in AD

The term MCI as reported by Petersen and colleagues [18] indicates a condition, generally affecting older individuals, characterized by isolate memory deficits. According to the diagnostic criteria for MCI, memory complaints referred by the patient have to be confirmed by a relative and/or a General Practitioner. Cognitive decline has to be greater than that expected for an individual's age and education level but such that does not interfere notably with daily life activities. The memory impairment must be documented by a performance falling below -1.5 standard deviation at memory tests. Furthermore, a diagnosis of overt dementia has to be excluded.

Petersen and colleagues [2] have classified MCI into three subtypes: I, amnesic; II, multiple-domain slightly impaired; and III, single non-memory domain impaired. The criteria for amnesic-MCI are specified by Petersen [19] as: memory complaints (preferably corroborated by an informant); objective memory impairment on a delayed recall test; relatively normal general cognitive functioning, with the exception of memory (other cognitive domains may be impaired but only to a minimal degree); and normal or only minimally impaired daily activities. Non-amnesic MCI can be further classified by the impairment in a single domain (language, executive function, visuospatial relations) or in multiple domains (combination of cognitive dysfunctions).

Even if data from the literature report high variability in the rate of conversion of MCI to AD [2,20,21], there is wide consensus that MCI is a positive prodrome of subsequent AD. The prevalence of dementia depends on the age group: 2.1/100 cases in 65-74 years, 6.9/100 cases in 75-84 years and 27/100 cases in the group beyond 84 years [22]. Kivipelto and colleagues [23] recorded a rate of MCI of 6% in people aged 65-79 years. According to Visser [12], the prevalence of MCI should vary between 2 and 30% in the general population and between 6 and 85% in clinical settings. As suggested by Amieva and colleagues [20] the

rate of conversion to AD can rise up to 50% at 2-3 years from the initial stage. After 6 years, 80% of 76 MCI patients (mean age = 81 years) can convert to AD [2,24]. Several factors may account for the discrepancies often found in epidemiological studies and clinical statistics: the selected population, the screening and neuropsychological tools to assess memory functions and the criteria adopted to diagnose the disorder. When clinical criteria have been strictly applied, a prevalence of 3% in the elderly population has been reported [2].

According to some authors MCI, particularly of type II, is associated with higher risk in developing AD than pure amnesic-MCI [25]. Instead, Petersen and colleagues [2] point out that patients with amnesic-MCI are more likely to develop AD than non-amnesic MCI patients. Two longitudinal studies performed in a memory clinical setting with a follow-up of 2 to 3.8 years found that all subjects with multiple domain-MCI (md-MCI, divided in md-MCI with memory impairment and without memory impairment) who developed dementia at follow-up had AD [26]. Moreover, 71% to 80% of the cases with AD at follow-up had md-MCI at baseline, and only 15% to 29% had amnesic-MCI.

Busse and co-workers [27], studying a sample of 1045 dementia-free individuals aged from 75 to 99 years, showed that the positive predictive power for subsequent dementia (after 2.6 years) was higher for the criteria of amnesic-MCI (33%) and multiple domain-MCI (29%). Zanetti e colleagues [28] found that subjects with amnesic-MCI who developed dementia at follow-up all had Alzheimer-type dementia, whereas subjects with multiple impaired cognitive domains MCI (md-MCI) who developed dementia all had vascular dementia.

Recent data from 269 Italian patients with amnesic-MCI report a conversion rate to dementia of 21.4% a year [29]; among them, about 83% resulted affected by AD. It is interesting to note that, in the same study, a large proportion of patients (24.1%) was still affected by MCI at 24-month follow-up, 13.3% had changed their neuropsychological profile, and 17.2% resulted cognitively normalized.

In sum, it is not yet clear which MCI sub-type is more likely to progress to AD and efforts to define more sensitive assessment tools and more precise classification criteria are necessary.

### 3. VISUOSPATIAL ABILITIES IN NORMAL AGING

MCI is typically defined as number of SDs from the normal average for different age groups. The boundaries between normal aging and dementia may comprise conditions in which heterogeneous patterns of cognitive impairment may be observed. Indeed, memory disorders with no dementia in the elderly population are frequently reported, and their prevalence varies from 22% to 56% [30]. Therefore, a clear picture of cognitive functioning and normal decline in healthy elderly adults has yet to be defined. Within the visuospatial domain, it is not clear which spatial components present a normal age-related decline, which ones are preserved and at what point the deficit is so severe to represent a sign of MCI. One reason of this variability is that spatial memory is not a unitary function but includes a wide range of processes and components [31,32]

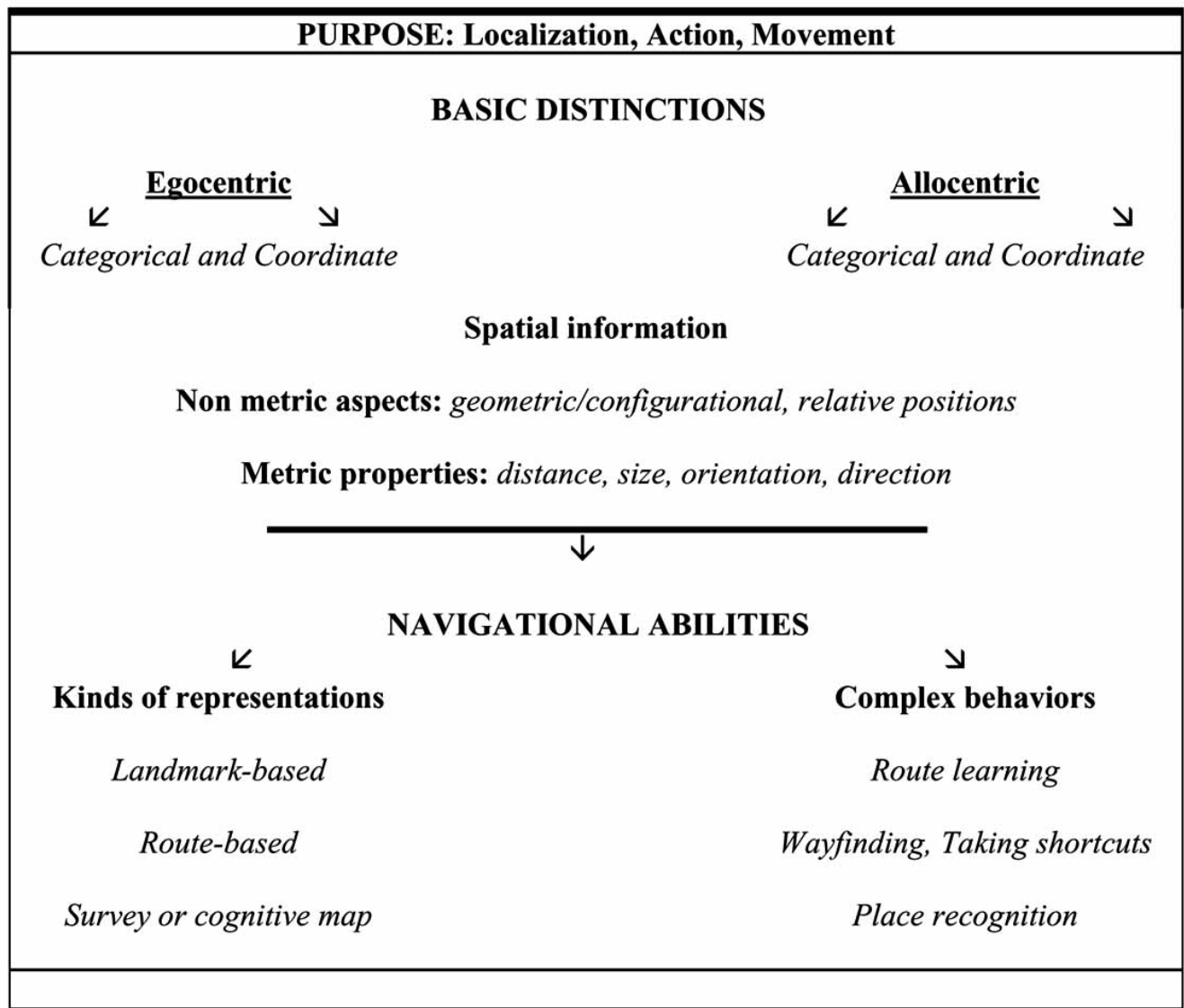
which could be selectively sensitive to aging effects. Consequently, it is important to use tasks clearly defined as regards the cognitive processing components and the spatial concepts measured. In the subsequent paragraph, a definition of what is "spatial" and basic models of spatial memory are provided.

#### 3.1. What is "Spatial"?

The term "spatial" is somewhat ambiguous as it has assumed different meanings and has been considered in various ways. For example, spatial competence is associated with the processing of geometric (or metric) properties such as distance and size, as well as dynamic properties such as velocity and strength. Clearly, the ability to navigate in the environment requires an understanding of all these properties, thus linking the idea of an intuitive geometry with that of an intuitive physics [33]. This ability is fundamental to our survival and it is not surprising that spatial abilities are often synonymous of navigational abilities. However, characteristics of objects such as size, orientation and location are also defined "spatial" [34]. Ungerleider and Mishkin [35] proposed a distinction between spatial information and object information in terms of "where" and "what" systems. The visual system comprises two different streams. According to the authors, the dorsal stream processes spatial or "where" information for object localization, whereas the ventral stream processes visual or "what" features (such as shape, color, luminance) for object recognition.

Potentially, all kinds of processes and information useful to locate positions and directions in the environment can be defined spatial. To encode the position of an object, a second object is needed that acts as a point of reference. Humans can use two fundamental classes of frames of reference to encode and organize in memory spatial information: egocentric and allocentric [36-38]. Egocentric frames of reference specify spatial information in relation to one's body and therefore maintain the viewing perspective. Egocentric spatial representations are often defined as orientation-specific or orientation-dependent [39]. Allocentric frames of reference are independent of the body's position and are centred on external elements such as objects and features of the environment [40,41, for a recent review see 42]. Allocentric spatial representations are not biased by the viewing perspective and are often called orientation-independent or orientation-free [39].

Kosslyn [36] proposed a distinction between two kinds of spatial information: one relies on categorical spatial representations which preserve non metric spatial relations between objects, such as object A is to the left of object B; the other relies on coordinate spatial representations which preserve locational information within a metric coordinate system, such as object A is 2 m far from object B. Therefore, this theoretical distinction specifies the grain of spatial information that links a point of reference (object B in the example) to other objects or locations, and is complementary to the egocentric/allocentric distinction [43]. In short, spatial relationships between the Self and external locations and between locations in space can be defined in terms of distances, directions and relative positions, and are



**Fig. (1).** Fundamental features of spatial memory as sketched in the text.

concerned with landmarks in the large-scale environment, objects and internal parts of objects.

As illustrated in Fig. (1), these two fundamental distinctions, i.e. egocentric/allocentric frames and categorical/coordinate information, form the basic structure of spatial memory and afford complex representations and behaviors. We can represent our environment as an allocentric survey map with embedded directions and distances or as a route sequence with left-right turns from a first-person egocentric perspective or we can simply focus on isolated landmarks [44].

These three levels of spatial representation, landmark, route and survey, form the developmental model proposed by Siegel and White [44] to explain the acquisition of spatial knowledge in the child. Then the model has been extended to the development by adults of knowledge of the environment and spatial strategies [45]. We can use diverse navigational strategies to find out our way in the environment and to act with objects. The fundamental role of spatial processes

between action and cognition is highlighted by Milner and Goodale [46] in their re-interpretation of Ungerleider and Mishkin's model. They proposed that the ventral stream generates object-centered, allocentric representations to the purpose of building up long-term representations of objects, whereas the dorsal stream generates egocentric representations necessary to plan and execute reaching movements under the guidance of vision. Finally, visuospatial information and processes enable non verbal cognitive abilities, such as mental imagery, that can be defined as the capacity to represent and manipulate information by relying on a spatial medium [36].

### 3.2. Models and Neurofunctional Bases of Spatial Memory

The neural mechanisms underlying spatial memory have yet to be fully understood, but it is agreed that the hippocampus, together with its fundamental role in general memory, is a key structure in supporting spatial memory.

The experimental evidence is robust and encompasses studies involving rodents, non-human primates and humans [see 47,48]. According to one influential theory, spatial information is maintained in the hippocampus in the form of a cognitive map, which specifies the directions and relative distances between locations in the environment [37,49]. Spatial information is integrated into an allocentric representation that is maintained in long term memory. More recently, it has been proposed that egocentric and allocentric information is processed in parallel in the parietal lobe and the hippocampal formation, with final transfer to the hippocampus for long-term storage in allocentric coordinates [50-52]. However, there is still debate on the status of long-term spatial memory: according to one view egocentric representations would be transient to the service of perceptual control of movement in space whereas only stable allocentric representations would be stored [53,54]; according to another view both egocentric and allocentric representations would be maintained [41]. In any case, the involvement of the hippocampus in allocentric spatial memory is commonly accepted (for review see [55]).

Few studies have investigated directly the cerebral networks subserving egocentric and allocentric processing. A fMRI study showed that egocentric information activated posterior parietal and lateral frontal premotor regions, more extensively in the right hemisphere [56]. A succeeding study confirmed the involvement of the fronto-parietal network in the egocentric processing, while a subset of these regions was also involved in the allocentric task [57]. Committeri and co-workers [58] compared viewer-centered, object-centered and landmark-centered spatial coding of visually presented realistic 3D-information. Viewer-centered egocentric coding activated mainly areas in the dorsal stream and in frontal lobes, whereas allocentric coding recruited both dorsal and ventral regions [58]. Zaehle and colleagues [59] found that the processing of egocentric spatial relations is mediated by medial superior-posterior areas with an important role of the precuneus, whereas allocentric spatial coding requires an additional involvement of the right parietal cortex, the ventral visual stream and the hippocampal formation.

With an ecological fMRI procedure, Rosenbaum and collaborators [60] assessed participants familiar with the city of Toronto in several navigational tasks: judgment of relative distance, estimation of distance, correct order of sequences of landmarks and spatial problem-solving. These tasks were associated with cerebral activation of the medial temporal lobe, in particular involving the right parahippocampal gyrus, and of the following areas: retrosplenial cortex (allocentric processing), medial and posterior parietal cortex (egocentric processing), prefrontal cortex (spatial processing requiring executive functions).

Maguire and colleagues [61] adapted a virtual reality paradigm to a PET procedure. Normal subjects had to mentally navigate to a goal, both directly and with detours. Direct navigation strongly activated the right hippocampus and the right inferior parietal cortex. Navigation with detour also activated the left superior and middle frontal gyri. An activation of the right caudate nucleus was also observed. In a second fMRI study normal subjects had to learn a route in a virtual environment and then to give judgements about

either the appearance (landmark processing) or the position of particular locations (survey processing). Landmark processing activated the lingual and fusiform gyri of the occipital cortex, whereas survey processing activated the posterior parietal and premotor areas. The overall data were interpreted in terms of a specific mental navigation network which included the right hippocampus, the left precuneus and the insula [see also 62].

As regards coordinate and categorical spatial representations, neuroimaging [63] and neurofunctional data [64] in normal subjects performing spatial imagery tasks have shown that the right hemisphere is particularly involved in processing coordinate metric relations, while the left hemisphere seems more specialized in computing categorical spatial relations.

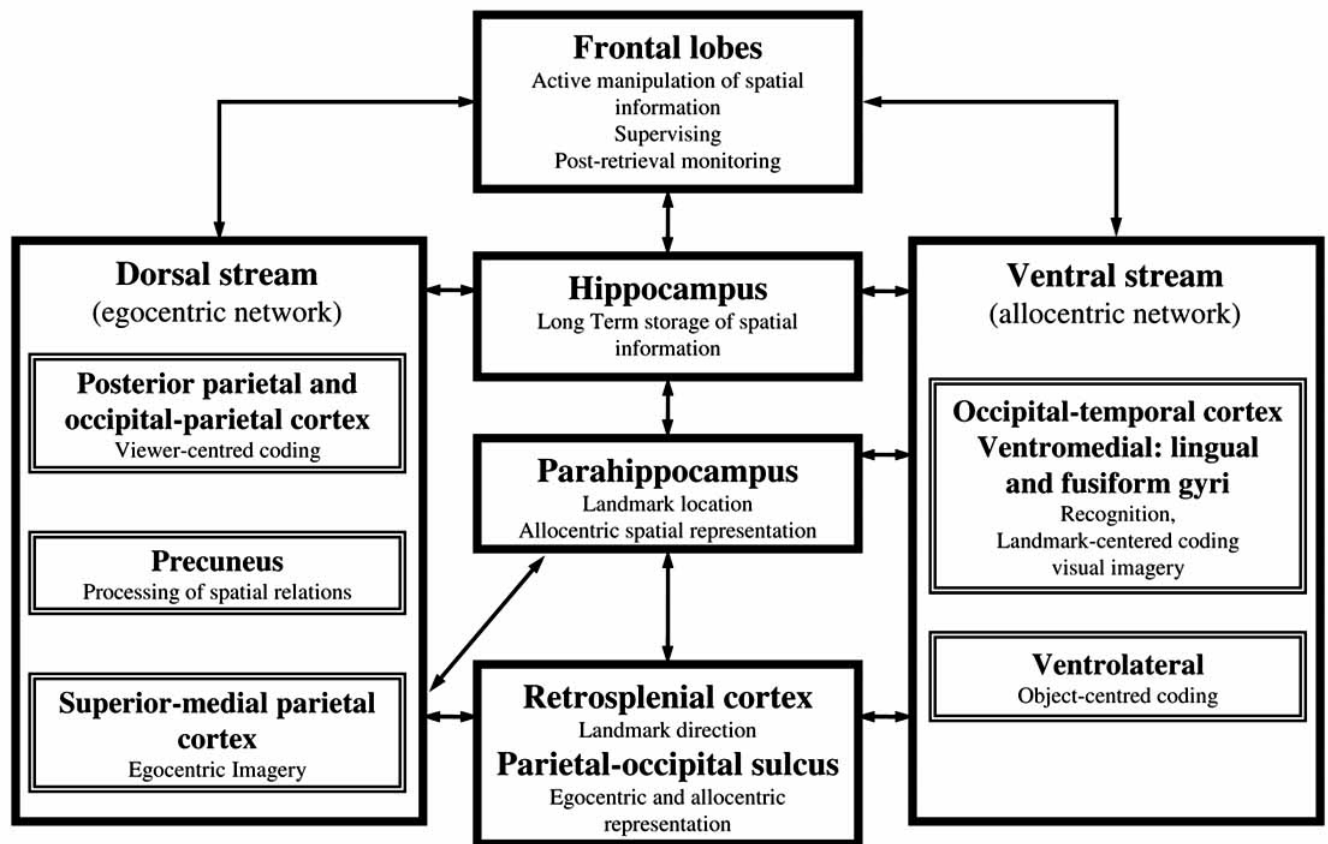
Recently, Iachini and colleagues [65] compared left- and right-parietal brain lesioned patients on an egocentric and allocentric spatial memory task. The results suggested that the right hemisphere is specialized in processing metric information according to egocentric frames of reference.

In conclusion, the heterogeneity of functions and processes of spatial memory is reflected in the complexity of the underlying cerebral networks, with a central role of hippocampal and fronto-parietal circuits. Fig. (2) provides a tentative description of the cerebral areas more involved in spatial memory.

### 3.3. Spatial Memory and Normal Aging: General Hypotheses

The reasons to study spatial memory and aging are multiple. First, spatial ability plays a fundamental role in everyday human activities, like way-finding, geographical orientation, using a map of space for navigation, localizing places or grasping objects. The assessment of visuospatial abilities, which are the necessary pre-requisite of independent mobility in the environment, is therefore crucial to monitor elderly people's well-being. Second, episodic memory is particularly vulnerable to decline with aging and is among the firsts and most profound deficits of dementia. Episodic memory has an inherently contextual nature, i.e. previous experiences are embedded in a spatial and temporal structure [66]. Spencer and Raz [67] reviewed the literature about age differences in episodic memory by distinguishing memory for content and context of a message. The results of the meta-analysis showed that age differences in context memory were reliably greater than those in content memory. Third, spatial memory is a basic component of more general, complex and non verbal cognitive processes such as mental imagery.

Age-related changes in basic visuospatial abilities, mental imagery and navigational abilities have been investigated. Laboratory-based psychometric tasks, such as mental rotation, and more ecological tasks, such as direction-finding and map learning have been used [68]. The results obtained are still controversial and it is not yet clear which spatial processes decline with age and which ones are preserved. Some data suggest that working memory is a very important structure in understanding cognitive aging and it has been hypothesized that a variation in its capacity is one of the main variables associated with reduced mental



**Fig. (2).** Graphic illustration of the relationships among neocortical regions, dorsal and ventral streams and hippocampal formation . The arrows indicate the connections among cerebral structures that allow the processing of spatial information.

efficiency. Salthouse and Mitchell [69] suggested that in working memory it is possible to distinguish between a structural component, i.e. number of information units that can be memorized at the same time, and an operational capacity component, i.e. number of processing operations that can be performed. Mayr and collaborators [70] reported pronounced age differences in active tasks requiring the integration and coordination of information. In a series of studies, Iachini and colleagues [32,71,72] compared two general hypotheses about the cognitive decline associated with healthy aging: the Slowing view and the Limited Resources view. According to the first view, the speed of cognitive processes is the main mediator of decrease with age and would have global and uniform effects on cognitive functioning [73,74]. According to the second view, age-related decline is a consequence of reductions in basic processing resources such as attention and working memory [75,76]. This hypothesis predicts selective age-related effects depending on the complexity of the task at hand. Iachini and colleagues [71] compared young and elderly healthy adults in a battery of psychometric tests assessing general cognitive functions (Story Retell, immediate and delayed, Attentional Matrices, Token, Verbal Fluency, Frontal Assessment Battery (FAB) devised by Dubois, Raven's matrices), and visuospatial abilities: Line length perceptual judgement, Mental rotation, Mental construction (all perceptually-driven), visuospatial working memory span (Corsi), Line length memory and Line Length inference. The results showed selective effects of aging. Some abilities were well

preserved, such as memory for line length and perceptual discrimination of line length. Some others were instead impaired, such as the ability to infer new information from memorized spatial information, the ability to manipulate the spatial structure of mental images and to construct mental images, and the ability of abstract spatial reasoning. Further, basic processing resources such as attentional capacity and visuospatial working memory showed a reduction in the elderly. Two subsequent studies [32,72] confirmed that aging has a detrimental effect on tasks that require active manipulation and strategic control of spatial information (the abilities to mentally rotate visual images, to retrieve spatio-temporal sequences and to infer new spatial information). Consistently, age had no detrimental effect on more passive tasks requiring only perceptually-based comparisons or pure maintenance of spatial information.

An interpretative framework similar to the Limited Resources View is offered by the active/passive model proposed by Cornoldi and Vecchi [77] within the Working-Memory domain. The model is based on the level of activity that cognitive processes require, that is the amount of integration, modification or transformation of information. Passive processes correspond to the simple maintenance of information, whereas active processes imply simultaneous maintenance and manipulation of information. Vecchi and Cornoldi [78] compared young and elderly healthy adults on passive and active visuospatial tasks. The battery included the Corsi test, the Visual Pattern task, the Mental Pathway task and the Jigsaw-Puzzle task. In the Jigsaw-Puzzle task,

participants are presented with numbered fragmented pictures of everyday objects that must be assembled by writing down in a blank grid the corresponding numbers. The Visual Pattern task consists in the presentation of pathways in matrices with increasing number of squares; participants have to reproduce these pathways in a blank matrix. In its Active version, the response matrix is presented in a different orientation and hence mental rotation of original pictures is needed. Overall, the results showed marked differences due to active tasks and suggested that age-related decline is due to a reduced capacity to manipulate and transform visuospatial information (see also [69]).

### 3.4. Basic Visuospatial Abilities in Normal Aging

As regards the egocentric/allocentric distinction, to the best of our knowledge the literature on aging and spatial cognition has not directly addressed this issue. In general, several spatial tasks have been used, such as pointing tasks, and the results are interpreted as consistent with the allocentric or the egocentric organization of spatial knowledge. Few attempts to compare directly these two kinds of processing with young people have been made [58,79] and it would be of theoretical and clinical relevance to determine their developmental course. Parkin and colleagues [80] used a spatial discrimination task that involved egocentric spatial memory to compare elderly and young people. They found no significant negative effect of age on the spatial performance, but only a slight decline.

As regards the coordinate/categorical distinction, only one study has addressed directly this issue. Meadmore and co-workers [81] studied the hemispheric specialisation and the effect of age on categorical and coordinate processing. The results showed in all age groups a left hemisphere advantage for the categorical task and a right hemisphere advantage for the coordinate spatial task. However, older adults were slower to process information and provide spatial judgements. The results, therefore, did not clarify if age exerted a selective negative impact on the two kinds of processing. Again, this gap should be filled in future research.

An important basic spatial ability is object location memory. Sharps and Gollin [82] reported that memory for objects and their spatial locations was more facilitated in older than younger adults when items were studied in a distinctive visual context. In Cherry and Park [83] younger and older adults had to study and later recreate an arrangement of small objects that were placed on a plain map or a visually distinctive context. The objects were either unrelated or categorically related. The results indicated that the distinctive context enhanced spatial memory in all age groups, whereas working memory resources accounted for an important proportion of age-related variance in memory for spatial location. Uttl and Graf [84] studied memory for spatial locations within a museum and a secretarial office. In Experiment 1 the subjects were 302 visitors (years from 15 to 74) to the museum; in Experiment 2 subjects were two groups of young and older adults. The results showed an age-related decline that appeared around the sixties. Cherry and Jones [85] assessed the effects of structural and organizational spatial context on memory for an arrangement

of dollhouse furniture pieces in younger and older adults. For half of the participants, landmark objects and a floor plan beneath the array served as structural context. Organizational context was varied by grouping items either randomly or prototypically. Landmark structural cues improved younger adults' performance, whereas both groups benefited from the floor plan. Connelly and Hasher [86] compared older and younger adults on a composite object location task. They found evidence that inhibition of identity and location may function separately within the dorsal and ventral visual streams. The findings are discussed in terms of reduced inhibitory efficiency of irrelevant information in the elderly.

Overall, these studies tell us that contextual factors and attentional/executive resources play a major role in the spatial memory decline normally associated with healthy aging. However, it is not clear which specific contextual factors are particularly susceptible to age effects and how they interact with executive factors.

### 3.5. Visuospatial Abilities and Mental Imagery

Mental imagery can be defined as a perceptual-like representation of external objects or scenes that is able to simulate a sensory-motor interaction with the environment in absence of actual sensorial stimuli [36]. In this domain, mental rotation and mental scanning of spatial images have been among the firsts and most studied imagery processes, possibly because they helped to clarify the spatial nature of imagery [87,88].

Research on mental rotation has shown that this ability declines with age [e.g. 89-92].

Craik and Dirks [93] reported a negative impact of age on visuospatial imagery using three different tasks: the Brooks Letter Test (subjects have to imagine walking along a block letter and describe the way), the East-West Test (subjects have to state the direction they are facing after changing direction), and the Clock Test (subjects have to state whether the hands of an imagined clock subtend an angle greater than 90°). Dror and Kosslyn [94] studied the effects of aging on four components of mental imagery: image generation, image maintenance, image scanning, and image transformation. The authors found a progressive impairment with age in image generation and rotation, but not in image maintenance and scanning. Further studies about generation and maintenance of mental images confirmed this trend and showed a prevalence of self-related images in the old [95,96].

Finally, some works addressed the topic of how metric properties, such as distance, are processed by means of a mental scanning paradigm [88]. Brown, Kosslyn and Dror [97] found that as the scanning distance increased perceptual and mental scanning of a small squared grid became harder for the elderly than it did for the younger. Iachini, Poderico, Ruggiero and Iavarone [71] adopted a mental scanning procedure that was adapted to an ecological situation: young and old participants had to study by vision and locomotion a real 3-D pathway and then had to mentally explore it. The results showed that aging had a negative impact on the quality of metric information embedded in mental maps of that environment. Elderly people retrieved the various

positions in their correct order, but were not able to depict consistently in their mental map the different distances.

### 3.6. Visuospatial Abilities and Navigation

A review of the literature [98] shows a clear decline of spatial abilities in the elderly when abstract laboratory tasks are used, whereas the decrement seems to reduce with more familiar tasks set in ecological contexts. For example, elderly people can cope effectively with several everyday spatial tasks [99]. Kirasic [100] found no negative effect of age when elderly people had to perform their spatial tasks in a familiar environment. Elderly participants can cope effectively with tasks requiring self-orientation in familiar environments and tend to judge their sense of direction more positively than the younger [90].

However, even in more ecological tasks there is evidence showing that age has a negative impact on various navigational abilities: selecting and remembering landmarks [101], learning unfamiliar routes [99,100], inferring distances and directions among locations [102], and finding the way [68]. A number of studies have found that older adults tend to perform worse than young adults on many measures of memory for routes [103]. Age differences favoring young adults have also been reported in learning how to navigate through real [104,105] or virtual [106] environments. Typically, in a route learning task participants have to explore a real path or a fictitious map and then to answer various questions. Salthouse and Siedlecki [107] investigated whether the age-related decline in navigational abilities is due to reduced efficiency in route selection. The results confirmed a moderate decline in measures of the efficiency of route selection as age increased from 18 to 93 years. This finding is consistent with the results of similar studies [108] and suggests that the age-related decline is due to a deficit in the planning of the pathway rather than in its execution.

Finally, a very popular task to assess navigational abilities is the Morris Water Maze test (MWM). In its standard version it is settled in a circular pool and the aim is to reach an invisible platform, located under the water level. As the target is not visible, it must be located with reference to several cues. Several versions of MWM have been designed to test human participants [109]. Moffat and Resnick [106] adopted virtual reality to test healthy elderly participants in MWM. They found that old participants, as compared to young adults, covered a greater distance to locate the hidden target, took shorter and showed greater difficulty to set up a cognitive map of the environment. Moffat and co-workers [110] also used the Virtual Water Maze to assess possible relationships between navigational abilities and structural integrity of hippocampal and extrahippocampal brain regions. The results confirmed that age-related deficits in navigational ability do not depend solely on the hippocampus but are also associated with larger regional volumes of multiple cortical and subcortical structures.

## 4. VISUOSPATIAL ABILITIES IN AD AND MCI

At a first look, works measuring visuospatial abilities in AD and MCI patients and reporting disturbances are huge,

about 709 articles. A closer reading led us to restrict our interest to few articles and to exclude the remaining for two main reasons: the terms visuospatial and visual were sometimes used as synonymous in reference to tasks requiring visual analysis of object properties; the assessment of visuospatial abilities often relied on measures poorly specified from a cognitive point of view. In our opinion, a careful identification of the task demands is essential in order to understand both the nature of the affected cognitive processes and the sequence in which such effects may occur.

For example, many researchers use constructional tasks that require participants to copy or to remember complex figures such as the Rey-Osterrieth test [4,111-115], the most used in the literature. Similarly, the Block Construction from the Performance subtests of the Wechsler Adult Intelligence Scale-Revised [116,117] requires to arrange painted wooden blocks in order to copy a design formed by the examiner or shown on a diagram. Both tests make demands on several cognitive components, including planning and praxis, as well as visuospatial abilities; this complexity does not allow to separate the relative contribution of visuospatial and executive components. Some works use the Raven's Colored Progressive Matrices [118] to assess visuospatial abilities [111,113,114]. Although the Raven test implies visual and geometric materials, assesses a complex and general ability such as abstract reasoning. Finally, other researchers use the Tower of London [119] and the Trail Making Test [120], that can be better considered as executive function tests, even if a visuospatial component may be implied.

Some tests clearly tap visuospatial abilities: Clock Drawing [121], Benton Line Orientation [122] and Dot Counting [123]. In all these cases, perceptual discrimination of simplistic visual stimuli is measured. To measure topographical orientation, it is often used the Money Road Map test [124] in which subjects have to trace a route on a map while identifying left and right turns [125,126]. Route-description and map-drawing tests are usually adopted to evaluate Topographical Disorientation in AD patients, but they are ambiguous in their task demands [10]. As an example, one could draw a map of a familiar environment by recalling either the route usually covered or the mental survey map of that environment: the final output would be the same although resulting from different spatial strategies (respectively egocentric/route and allocentric/survey). We selected about 20 studies investigating visuospatial disturbances in AD and MCI patients and using specific perceptual spatial tasks.

As regards spatial memory, the Corsi test is usually used to measure the short-term sequential memory span. It consists of a set of nine identical blocks arranged irregularly on a board. Participants have to reproduce the sequences of blocks of increasing length as tapped by the experimenter in forward-recall order and sometimes in backward-recall order [127,128]. The final score corresponds to the span length, that is the maximum level of block-tapping sequences reproduced.

About ten studies, discussed below, devised tasks that successfully removed the confounding elements of constructional praxis and object identity processing, and required memory for simple spatial arrangements or complex routes/environments.



#### 4.1. Visuospatial Perceptual Abilities in AD and MCI

The staging of visuospatial deficits in AD has not been investigated extensively and the few attempts to examine the relationship between patterns of deficit and age of patients are still inconclusive [4,123,129]. Initial interest in visuospatial abilities was motivated by the heterogeneity of deficits characterizing AD and the possibility to distinguish different subgroups of patients [130]. In these studies visuospatial abilities were assessed at perceptual level. Martin and colleagues [4,131] identified two subgroups of similar size (about 20% of their overall sample in each domain): one showed impairment of word-finding ability with preserved visuospatial and constructional skills, whereas the other one showed the opposite profile. The remaining group showed global cognitive decline. Complex tasks were used to assess the visuospatial domain (Rey, Block Design and Mosaic comparisons). Becker and colleagues [129] identified similar groups with focal deficits, although the percentage of visuospatial AD was only 5%.

Mendez and colleagues [5] used several visuo-perceptual tasks, including object, face and color recognition and form discrimination, to examine visual disturbances in AD patients. Deficits in spatial localization and object recognition were present in half the sample, which ranged from mild to severe stages of the disease. They concluded that complex visual disturbances such as deficits in figure-ground discrimination, visual object recognition and spatial localization are common in AD.

Kaskie and Storandt [132] used a complex test, the Visual Form Discrimination, to compare very mild and mild AD patients with healthy controls and found visuospatial deficits in several AD patients. Kurylo and colleagues [133] found that scores on tests of visual processing did not correlate with severity of dementia and suggested that visual deficits may reflect the heterogeneity of neuropathological changes rather than overall disease progression. Nordlund and colleagues [134] examined attention, memory and learning, visuospatial functions, language and executive functions in MCI patients and matched controls. The results showed impairments in all five cognitive domains.

The assessment of visuospatial abilities first demonstrated the heterogeneity of degenerative deficits and then led to the hypothesis that they could represent an early predictor of AD [135]. For example, interest in possible visual mechanisms underlying topographical disorientation in AD patients led to hypothesize that early visual motion perception deficits could precede navigational impairments [136]. Mapstone and colleagues [125] compared young and older healthy adults with MCI and AD patients in perception of panoramic visual motion stimuli. One fifth of the older adults, one third of the patients with MCI, and half of the patients with AD showed pervasive impairments of visual motion perception that correlated with poorer performance on the Money Road Map test. In line with O'Brien and colleagues [136], the authors suggested that visuospatial deficits may develop as an early sign of neurodegenerative disease.

Pursuing the visuospatial hypothesis, Rizzo and colleagues [137] compared mild AD patients and healthy controls on tests measuring visual perception and general

cognition. AD patients showed deficits in static spatial contrast sensitivity, visual attention, shape-from-motion, visuospatial construction and visual memory. The findings are compatible with the hypothesis that neurodegenerative processes involve multiple visual neural pathways and visual dysfunctions may contribute to decrements in other cognitive domains.

In a PET study, Fujimori and colleagues [138] assessed spatial vision and object vision (based on the Milner and Goodale's model [46]) in 49 patients with mild-to-moderate AD. Spatial vision was tested by means of the Visual Counting test, whereas object vision by means of the Overlapping Figure Identification and the Visual Form Discrimination tests. The results showed that the visual spatial disturbance was correlated to the metabolic rate of the bilateral inferior parietal lobules, whereas the visual object disturbance was correlated to the right middle temporal gyrus and the right inferior temporo-parietal metabolism.

Caine and Hodges [123] examined the staging of visuospatial and semantic deficits in 26 minimal/ mild AD patients and healthy controls to determine whether visuospatial deficits may occur prior to the presence of semantic deficits. They emphasized that psychometric tests must be highly specific as regards the underlying cognitive requirements. Visuospatial abilities were assessed by tests based on visual perception: Line Orientation, Object Decision (where participants had to decide whether line drawings depicted real or unreal items) and Object Matching (where participants had to recognize a target object between two distractors: same object from an unusual view or different object but visually similar). In a second study the Visual Object and Space Perception Battery was used (VOSP) that included the Dot Counting test and two tests of positional discrimination. A small group of early AD patients showed visuospatial deficits and poor episodic memory without coexisting semantic impairment, and this suggested that damage can occur in occipito-parietal or parietal regions at an earlier stage than currently recognized. This study deserves some comments. First, Caine and colleagues [123] have the merit of adopting tests of spatial perception independent of executive, praxic or object-based components, although these tests used quite abstract and simplistic elements and did not assess more ecological situations. Second, the association of visuospatial and episodic memory deficits might imply that damage in visuospatial cerebral areas is primary and is responsible for memory losses, as discussed below.

In a fMRI study, Vannini and co-workers [139] investigated the visuospatial cerebral networks in 18 MCI patients. Along three years, they were periodically submitted to an extensive battery of tests that included: WAIS-R, Rey-Osterrieth Copy and Retention Test, Rey Auditory Verbal Learning Test [140], and Trail Making Test A and B [141]. To assess visuospatial abilities an angle discrimination task was adopted. The authors concluded that MCI patients who progress to AD revealed a reduced neuronal efficacy during execution of the angle-discrimination task. Furthermore, the increased activation in the left hemisphere in MCI converters suggested that compensatory mechanisms might be activated before the onset of clinical symptoms of AD.

In conclusion, all these studies raised the possibility that visuospatial abilities could represent an early predictor of subsequent disease. However, as the testing was limited to the perceptual level of spatial processing, the relative contribution of the visuospatial modality to the well-known memory deficits and its possible anticipatory role was not assessed.

#### 4.2. Visuospatial Memory Deficits in AD and MCI

There are few recent studies about the visuospatial modality in the memory process of AD and MCI patients. In the past years, it has been showed that memory for spatial locations [142], spatial patterns [143] and object locations in a grid [144] is impaired in AD patients as compared to normal controls. Apart from some recent investigations, there are no systematic data about AD and MCI patients. Here we review those few studies assessing basic and navigational visuospatial memory processes and adopting clearly defined tasks (see Table 2 below).

Vecchi and colleagues [145] compared 16 early-stage AD patients with a healthy elderly group in order to determine the contribution of passive and active processes in the limitations of working memory functions observed in AD. There were four tasks: a verbal passive task, a verbal active task, the Corsi test and a visuospatial active task (Mental pathway). The results showed that AD patients performed less accurately than the control group in all tasks, but the deficit was maximized with active verbal and spatial processes. Therefore, a clear impairment of executive processes was confirmed while the staging of verbal and spatial deficits remained unclear, presumably because of the lack of MCI patients in the sample.

Lineweaver and colleagues [146] submitted AD patients to a mental rotation task and found that accuracy decreased as rotational angle increased. According to the authors, the spatial manipulation deficit of AD patients may reflect pathology in parietal and temporal lobes.

Some works have found an impairment in visuospatial short-term memory as measured by the Corsi test in very mild and mild AD patients [111] and in AD patients followed for two years [113]. The authors suggested that visuospatial deficits might constitute an early predictor of AD and that cognitive decline may be better predicted by deficits diffused in linguistic and visuospatial domains.

Toepper and co-workers [147] compared 13 AD patients with elderly controls on several tests (Block Suppression, clock drawing, digit-word transformation, verbal memory span). Interestingly, the Corsi test was used in forward and backward orders. The results showed that in AD patients the active inhibition of irrelevant stimuli and the Corsi backward span were significantly reduced, confirming the substantial impairment in attentional and executive resources.

Kessels and colleagues [148] investigated object-location memory in 18 AD patients and a matched control group by using an ecologically valid computer task in which participants had to remember the locations of objects in common rooms. There were colored photographs of eight domestic rooms and 80 everyday objects that were semantically related to these rooms. Participants had to learn the locations of various objects and next to relocate these

objects to their original locations. The results showed an impairment of explicit but not implicit spatial memory in AD patients. This suggests that the preservation of implicit memory in AD extends to the spatial domain, and this could have an important rehabilitative value.

Kavcic and colleagues [126] compared 15 AD patients and matched controls to assess navigational impairments in AD. They measured visual motion evoking potentials responses to optic flow simulating observer self-movement to verify how these potentials were linked to navigational performance. Participants were submitted to a neuropsychological battery that included visuospatial tests such as the Money Road Map and the Judgement of Line Orientation and to a real-world navigational task. Participants were led with a wheelchair along a route and then asked several questions that assessed their knowledge of the route, of the landmarks and both. Afterwards, there were three route learning tasks: re-trace the route by indicating which turn was taken previously, point to several locations from the starting/finishing positions and draw the route on a map. There were three landmark tasks: name as many landmarks as possible from the route, name features that could help in finding the way along the route and recognize views of the route depicted on photographs. Two tasks assessed the integration of route and landmark knowledge: identify which direction allowed to see the viewpoint shown on photographs and indicate the direction and extent of movements shown on video clips. The results showed that the navigational impairment in AD patients was linked to a disorder of extrastriate visual cortical motion processing that was reflected in specific perceptual and memory measures of spatial abilities.

deIpolyi and collaborators [114] compared 13 mild AD and 21 MCI patients with matched controls on a route-learning task and a neuropsychological battery. In the route-learning task, subjects were led along a novel route through a Care Center. Subsequently, they had to repeat the route by giving themselves the proper directions and to draw the route on a map. Next, subjects were shown with three sets of photographs and had to recognize: photographs of objects and places along the route (Landmark Recognition), the position of places along the route (Landmark Location) and the order in which several targets were encountered along the route (Order Memory). Finally, subjects were asked to traverse the route from the end to the start and were submitted to a pointing task. A subsample also took part in a neuroimaging study to determine the neural correlates of the tested spatial abilities. The results showed that AD and MCI patients recognized landmarks as effectively as controls, but could not find their locations on maps or recall the order in which they were encountered. Half of AD and one-quarter of MCI patients got lost on the route, compared with less than 10% of controls. Patients who got lost had lower right posterior hippocampal and parietal volumes than patients and controls who did not get lost. The ability to identify locations on a map correlated with right posterior hippocampal and parietal volumes, whereas order memory scores correlated with bilateral inferior frontal volumes. In sum, the navigational disability in AD and MCI patients involved a selective impairment of spatial cognition, presumably concerning the capacity to represent environmental information at route level. This deficit was

**Table 2. Relevant Studies Investigating Visuospatial Abilities in Healthy Elderly, AD and MCI**

References	Year	Sample/s	Main Visuospatial Task/s	Results
[143]	1988	12 AD, 27 PD and 39 matched NC	Computerized tests of visuospatial memory	The AD patients were severely impaired in the visuospatial memory task
[142]	1992	15 mild AD, 16 moderate AD and 16 NC	Spatial order and spatial recognition memory tasks	Mild AD patients were impaired in memory for early serial positions, while moderate AD patients on all serial positions for both spatial order and spatial recognition memory
[144]	1997	19 AD, 12 VAD and 29 NC	Location Learning Test (LLT)	The AD and VAD patients were impaired in the LLT
[145]	1998	16 AD and 16 NC	A verbal passive task, a verbal active task, Corsi test, a visuospatial active task (Mental pathway)	AD had lower performances than NC. The deficit was maximized in active processes
[148]	2005	18 AD and 18 matched NC	Rooms Task	Impairment of explicit spatial memory in AD, but no difference with the control group on implicit spatial memory
[146]	2005	18 AD, 18 HD, 36 matched NC	A computer based mental rotation test	The accuracy of AD patients decreased with increasing angle of orientation
[126]	2006	15 AD and 15 NC	Money Road Map test, Judgement of Line Orientation test, a real-world navigational task	AD patients showed deficits of visual motion processing and were not able to link navigational information into an integrated cognitive map of the environment
[111, 113]	2006, 2007	36 AD (18 Very mild AD, 18 mild AD) and 17 NC 43 AD: 22 fast CD and 21 slow CD 43 in a longitudinal study (24 months)	Corsi test	AD patients were impaired in Visuospatial short-term memory
[8]	2007	8 AD, 8 MCI and 8 NC	Visual short-term memory (VSTM), and visuospatial short term memory (VSSTM) tasks	VSTM and VSSTM deficits in MCI and AD patients, VSSTM deficits were more severe in AD
[114]	2007	13 mild AD, 21 MCI and 24 matched NC	A route-learning task (RTL) comprising: RLT-Forward, Landmark Recognition, Landmark Location, Order Memory, RLT-Reverse and Dead Reckoning sub-tasks	AD and MCI patients recognized as many landmarks as controls, but could not find their locations on maps or recall the order in which they were encountered
[9]	2007	21 AD, 36 MCI, 8 SMC and 26 NC	Adaptation of MWM	Impairment in the allocentric component of spatial memory in aMCI, overall spatial impairment in AD and multiple domain aMCI
[147]	2008	13 AD and 13 NC	Block Suppression, clock drawing, digit-word transformation, verbal memory span, Corsi test (backward and forward)	AD patients were impaired in active inhibition of irrelevant stimuli and in backward span
[149]	2008	29 aMCI and 30 NC	Brief Visuospatial Memory Test-Revised (BVMT-R), Digit Symbol incidental recall	Early neuroanatomical changes in the hippocampus and entorhinal cortex in aMCI cause the impairment of the ability to integrate associative information in memory

**Abbreviations:** AD = Alzheimer’s disease patients; MCI = mild cognitive impairment patients; aMCI = mild cognitive impairment patients amnesic domain; NC = normal control participants; SMC = elderly people with subjective memory complaints; PD = Parkinson’s disease; HD = Huntington’s disease patients; VAD = vascular dementia patients; MWM= Morris Water Maze.

associated with atrophy of the right-lateralized navigation network. Therefore, we can comment that by joining the behavioral methods of cognitive psychology and the neuroimaging techniques of neuroscience, this study was able to detect parallel changes at behavioral and neurofunctional level in the navigational abilities. Notably, the authors adopted navigational tasks that required specific processing components within the complex domain of spatial memory. The extensive spatial impairments observed in MCI patients suggest that navigation tests may help to find out early markers of dementia.

Troyer and colleagues [149] compared 29 individuals with amnesic MCI and 30 matched controls on standardized tests of object–location recall and symbol–symbol recall. The amnesic-MCI group showed marked deficits in the ability to integrate associative information in memory, and this was attributed to early neuroanatomical changes in the hippocampus and the entorhinal cortex. According to the authors, then, associative memory deficits may represent an early cognitive sign of AD.

Finally, two recent studies suggest interesting hypotheses about the predictive role of specific spatial memory processes. Alescio-Lautier and colleagues [8] compared 8 MCI and 8 AD patients with healthy controls to determine which modality, i.e. visual or visuospatial, is more implicated in the early memory impairment typical of AD. In the visual short term memory (VSTM) task, patients had to encode a composite image comprising various concrete objects and to recognize whether these images changed or not. In the visuospatial short term memory (VSSTM) task, patients had to encode the location of similar images and had to recognize if the entire pattern changed or not its position. A span control task was used to determine the number of images with which patients could perform the recognition task at their memory capacity level. After each presentation, a target image was presented at three different intervals (1sec, 10sec, 30sec) and the participants had to recognize if images (VSTM) or locations (VSSTM) had changed. In order to disentangle the relative contribution of attentional resources in the memory impairment, for half trials a distractor in the interval between the presentation and the recognition was presented. Results showed VSTM and VSSTM deficits in MCI and AD patients as compared to elderly healthy controls, with the spatial performance being worse than the visual one. MCI patients had an intermediate performance between controls and AD patients. However, cognitive memory profiles differed between MCI and AD patients depending on the modality tested and this indicated an alteration of different processes. Indeed, AD patients presented a greater deficit in the visuospatial modality than MCI patients and were differently affected by the experimental manipulations. In the visual recognition task, AD patients had more difficulty with the no change condition (in which images were the same) than the change condition, whereas this did not happen with MCI patients. The incapacity to detect no change was explained by the phenomenon of attentional blink: a temporary functional blindness to the second of sequentially presented stimuli. Further, the span measure could have affected the VSTM task with more errors as the number of images increased. In the VSSTM task the set of images can be considered as a whole and this should have facilitated the performance,

although it did not. Consequently, the deficit in the VSTM task might depend on the number of images, whereas in the VSSTM task it should be due to the spatial component rather than the visual one. When the distractor was presented in the VSTM task, more errors appeared at 1sec interval than in other intervals. Instead, the visuospatial task was not so sensitive to the presence and timing of the distractor. The visual recognition deficit, then, could derive from an impairment in disengaging-engaging attention in MCI and AD patients. The overall results, therefore, suggest that deficits in visual recognition are secondary to impairments in attentional and executive resources, whereas deficits in spatial recognition are primary and reflect a genuine spatial disorder. They might also imply that visuospatial short-term deficits appear earlier than visual short-term ones in the disease progression. Studies based on the complementary assessment of attentional resources and visuospatial memory, then, could help to identify the cognitive origin and the neurofunctional bases of the deficits shown by MCI and AD patients, and this is necessary to understand the staging of the deficits and their predictive value.

Hort and colleagues [9] investigated navigation deficits in AD and MCI patients in order to assess which spatial components of navigational ability could represent a positive marker of subsequent AD and in which sub-group of MCI patients this marker is present. The sample included 26 normal controls, 21 AD patients, 8 elderly people with subjective memory complaints (SMC) and 3 groups of MCI patients sub-classified according to the Petersen's criteria: 7 nonamnesic (naMCI), 11 amnesic single domain (aMCI), 18 amnesic multiple domain (aMCI<sub>md</sub>). They adopted the MWM test in a version that allowed to discriminate the allocentric and egocentric components of navigational ability. Participants were required to locate an invisible goal inside a circular arena, and to this purpose they could use either egocentric cues (the relationship between the goal and their starting position) or allocentric cues (external features). The results showed strong differences in the patterns of spatial navigation impairments among the subtypes of MCI. The AD and aMCI<sub>md</sub> groups were impaired in all conditions, whereas the naMCI and SMC groups were similar to controls. Finally, the aMCI group showed a specific impairment in the allocentric processing. The similarity of spatial navigation impairments in the aMCI<sub>md</sub> and AD groups confirmed that aMCI<sub>md</sub> could represent an advanced prodromal stage of dementia, whereas aMCI could represent an even earlier stage [25]. In sum, the authors suggest a developmental course starting from aMCI to aMCI<sub>md</sub> and finally to AD. The impairment in the allocentric component of spatial memory could allow the monitoring of the disease progression and could help in detecting the early stages preceding AD.

### 4.3. Neurofunctional Evidence in AD and MCI

On the basis of histological and neuropathological evidence, AD is characterized by degeneration of neurons and their synapses and by the appearance of neurofibrillary tangles and senile plaques that are considered generally linked to the hippocampus atrophy [150]. Studies investigating the changes in the levels of markers of tangle and plaque formations in the cerebrospinal fluid (CSF) have

shown a detectable potential index for diagnosis of conversion to degenerative dementia [151]. In particular, it seems that tangles and plaques, initially accumulated many years before the clinical onset of the disease, could correlate with the severity of the disease [152]. The degeneration seems to prefer cerebral structures such as the transentorhinal and the entorhinal cortexes, the hippocampus and, then, the neocortical associative areas. This involvement can explain the dysfunction of encoding and storing information that reflects deficits at the level of consolidation of information [6]. Furthermore, Apostolova and co-workers [150] found that a high risk for conversion from MCI to AD is associated with increased involvement of the hippocampal subregion (CA1) and the subiculum. As pointed out by Killiany and co-workers [153], the atrophy of some mesial temporal lobe structures could represent a predictor for the conversion from MCI to AD. Thompson and colleagues [154] reported losses of grey matter being faster in the left hemisphere than in the right one distinctively in AD with respect to normal aging.

Still, by adopting single photon emission computed tomography (SPECT) and positron emission tomography (PET), many studies demonstrated reduced blood flow and metabolic deficits in temporoparietal cortices in patients with AD [155]. Furthermore, damage in parietal cortex could indicate impairments in visuospatial processes that can be recognized in the early clinical stages of AD [156]. Accordingly, evidence from functional magnetic resonance imaging (fMRI) examining brain activation evoked by visuospatial processing, showed decreased activation in the dorsal visual pathway as well as compensatory recruitment of remote brain areas in AD patients [157]. From this perspective, Vannini and associates [139] argued that compensatory mechanisms may mask the starting degenerative process by determining functional changes. The same authors hypothesized that an increased parietal activation in MCI patients could reflect a reduced neuronal efficacy due to accumulating AD pathology as proof of a compensatory mechanism.

Given a predominance of temporal lobe damage, especially in early stages of AD, Kurylo and colleagues [133] suggested that it may be particularly useful to assess the dorsal-ventral streams, especially in relation to visual tasks. Visuoconstructional dysfunction in AD patients is significantly correlated with a lower metabolism in the right parietal cortex [158] or in the bilateral occipital and temporoparietal regions [159]. Pietrini and colleagues [160] showed that patients with visuospatial symptoms had larger metabolic deficits in the bilateral parietal and occipital cortices than did patients without the symptoms.

## CONCLUSIONS: SPATIAL MEMORY AND ALZHEIMER'S DISEASE

A great effort has been devoted to the definition of behavioral, biological and neurofunctional correlates which could predict the conversion of MCI in AD, but most studies have focused on verbally-mediated memory disorders. Surprisingly, in contrast with the number of studies addressed to disentangle the multiple cognitive processes subtending (normal) spatial memory, both with methods of cognitive psychology and neuroscience, there are relatively

few studies aimed at evaluating disorders of spatial memory in AD.

We believe it is worth exploring this topic for the following reasons. First, a progressive disorder primarily involving memory (including spatial memory) could be assumed as a theoretical paradigm to get insights into the nature of *normal* spatial memory. Second, the AD is a degenerative disease primarily involving brain structures (hippocampus and medial temporal lobes) heavily implicated in spatial memory processes. Consequently, studies on pre-clinical stages of AD (namely, the MCI), or AD in its early stages, could be assumed, with some limitations, as a "lesional" paradigm to evaluate the role of these structures in the complex organization of spatial memory. Studies on patients with focal brain damage have the limitation given by the wide heterogeneity of the site, extension and nature of the lesion, which prevent to carry on studies on large cohorts of subjects. Patients with AD or MCI, conversely, do not undergo these limitations, given the putative pathogenetic homogeneity of the disease and the relative simplicity to match them according to general cognitive functioning. Third, data from visuospatial functioning could be of great aid to detect patients in early stages of AD, in such a way to contribute to a timely diagnosis of dementia and to detect subjects with MCI at higher risk to develop AD.

In the above paragraphs it has been shown that spatial memory is heavily dependent on brain structures which exhibit a particular vulnerability to both normal aging and degenerative dementia. As shown in Fig. (2), the hippocampus, the fronto-parietal network and the temporal lobe are strongly involved in spatial memory. Researches indicate that the neurodegeneration in AD primarily disrupts hippocampus, which accounts for the early appearance of anterograde episodic amnesia. However, the hippocampus is also strongly implicated in visuospatial processes, like topographic orientation and allocentric processing, and this may account for the symptoms of spatial disorientation which may precede, in some cases, disorders of episodic memory. Furthermore, temporal-parietal areas, which are related to spatial and visuo-constructive abilities, are early involved in AD. The converging evidence about the neural circuits subserving normal spatial memory and about the evolution of the cerebral degenerative process suggests that subtle disorders of spatial functions could be associated with MCI and/or be considered a putative "cognitive marker" of risk of conversion to AD. However, if we aim at identifying very early pre-dementia states we have to adopt a research strategy that is able to detect functional changes before structural changes become evident. As suggested by Vannini and colleagues [139], a reduced metabolic rate in specific cerebral areas may precede future damages. To this purpose, it is necessary to join neuroimaging techniques and neuropsychological knowledge with experimental paradigms derived from cognitive psychology. Indeed, there is need of tasks clearly specified in their cognitive processing components and in the concepts measured in order to put forward hypotheses about the specific cerebral areas involved and about the correlation between behavioral changes and metabolic rate in those areas.

The results discussed above suggest that deficits in spatial memory may play an important role in this research

strategy. The impairment of the allocentric component of spatial memory found by Hort and colleagues [9] may underlie navigational deficits and, more importantly, deficits in broader cognitive processes such as object recognition [35,46]. Alescio-Lautier and colleagues [8] attributed visual recognition deficits in MCI and AD patients to attentional factors. In normal aging several cognitive deficits are mediated by a reduction in attentional and working memory resources: from this point of view only a quantitative difference between AD patients and healthy elderly would appear. Instead, spatial deficits seem primary and not secondary to attentional factors, consequently they could represent a qualitative marker of departure from normal aging. Further, if they were primary we could even speculate that the well-known episodic memory deficits might be due to spatial memory impairments or rather they may coexist. Nowadays there is not enough experimental evidence to state that spatial memory deficits occur earlier than other deficits in the disease progression, but there is enough matter to suggest deeper scientific investigation.

## REFERENCES

- [1] Hodges JR. Alzheimer's centennial legacy: origins, landmarks and the current status of knowledge concerning cognitive aspects. *Brain* 129: 2811-2822 (2006).
- [2] Petersen RC, Doody R, Kurz A, Mohs RC, Morris JC, Rabins PV, et al. Current concepts in mild cognitive impairment. *Arch Neurol* 58: 1985-1992 (2001).
- [3] Fox NC, Warrington EK, Seiffer AL, Agnew SK and Rossor MN. Presymptomatic cognitive deficits in individual at risk of familial Alzheimer's disease. A longitudinal prospective study. *Brain* 121: 1631-1639 (1998).
- [4] Martin A, Brouwers P, Lalonde F, Cox C, Teleska P, Fedio P, et al. Towards a behavioral typology of Alzheimer's patients. *J Clin Exp Neuropsychol* 8(5): 594-610 (1986).
- [5] Mendez MF, Mendez MA, Martin R, Smyth KA and Whitehouse PJ. Complex visual disturbances in Alzheimer's disease. *Neurology* 40: 439-443 (1990).
- [6] Braak H and Braak E. Neuropathological staging of Alzheimer-related changes. *Acta Neuropathol* 82: 239-259 (1991).
- [7] Carli M, Luschi R and Samanin R. Dose-related impairment of spatial learning by intrahippocampal scopolamine: antagonism by ondansetron, a 5-HT3 receptor antagonist. *Behav Brain Res* 82(2): 185-194 (1997).
- [8] Alescio-Lautier B, Michel BF, Herrera C, Elahmadi A, Chambon C, Touzet C, et al. Visual and visuospatial short-term memory in mild cognitive impairment and Alzheimer disease: role of attention. *Neuropsychologia* 45(8): 1948-1960 (2007).
- [9] Hort J, Laczo J, Vyhnaek M, Bojar M, Bures J and Vlcek K. Spatial navigation deficit in amnesic mild cognitive impairment. *Proc Natl Acad Sci USA* 104: 4042-4047 (2007).
- [10] Aguirre GK and D'Esposito M. Topographical disorientation: a synthesis and taxonomy. *Brain* 122: 1613-1628 (1999).
- [11] Petersen RC, Stevens JC, Ganguli M, Tangalos EG, Cummings JL and DeKosky ST. Practice parameter: early detection of dementia: mild cognitive impairment (an evidence-based review). Report of the Quality Standards Subcommittee of the American Academy of Neurology. *Neurology* 56(9): 1133-1142 (2001).
- [12] Visser PJ. Mild cognitive impairment subtypes and vascular dementia. *J Am Geriatr Soc* 54(12): 1966-1967 (2006).
- [13] Petersen RC. Challenges of Epidemiological Studies of Mild Cognitive Impairment. *Alzheimer Dis Assoc Disord* 18(1): 3-10 (2004).
- [14] Kral VA. Senescent forgetfulness: benign and malignant. *Can Med Assoc J* 86: 257-260 (1962).
- [15] Burns A and Zaudig M. Mild cognitive impairment in older people. *Lancet* 361(9364): 1227-1228 (2002).
- [16] Flicker C, Ferris SH and Reisberg B. Mild cognitive impairment in the elderly: predictor of dementia. *Neurology* 41: 1006-1009 (1991).
- [17] Petersen RC. Normal aging, mild cognitive impairment, and early Alzheimer's disease. *Neurologist* 1: 326-344 (1995).
- [18] Petersen RC, Smith GE, Waring SC, Ivnik RJ, Kokmen E, Tangalos EG. Aging, memory, and mild cognitive impairment. *Int Psychogeriatr* 9: 65-69 (1997).
- [19] Petersen RC. Mild cognitive impairment as a diagnostic entity. *J Intern Med* 256(3): 183-194 (2004).
- [20] Amieva H, Letenneur L, Dartigues JF, Rouch-Leroyer I, Sourgen C, D'Alché-Birée F, et al. Annual rate and predictors of conversion to dementia in subjects presenting mild cognitive impairment criteria defined according to a population-based study. *Dement Geriatr Cogn Disord* 18(1): 87-93 (2004).
- [21] Petersen RC and Negash S. Mild cognitive impairment: an overview. *CNS Spectr* 13(1): 45-53 (2008).
- [22] Jönsson L and Berr C. Cost of dementia in Europe. *Eur J Neurol* 12: 50-53 (2005).
- [23] Kivipelto M, Helkala EL, Hanninen T, Laakso MP, Hallikainen M, Alhainen K, et al. Midlife vascular risk factors and late-life mild cognitive impairment: A population-based study. *Neurology* 56(12): 1683-1689 (2001).
- [24] Morris J, Storandt M, Miller J, McKeel D, Price J, Rubin E, et al. Mild cognitive impairment represents early-stage Alzheimer disease. *Arch Neurol* 58: 397-405 (2001).
- [25] Alexopoulos P, Grimmer T, Pernecky R, Domes G and Kurz A. Do all patients with mild cognitive impairment progress to dementia? *Dement Geriatr Cogn Disord* 22: 27-34 (2006).
- [26] Rasquin SM, Lodder J, Visser PJ, Lousberg R and Verhey FR. Predictive accuracy of MCI subtypes for Alzheimer's disease and vascular dementia in subjects with mild cognitive impairment: a 2-year follow-up study. *Dement Geriatr Cogn Disord* 19(2-3): 113-119 (2005).
- [27] Busse A, Bischof J, Riedel-Heller SG and Angermeyer MC. Subclassifications for mild cognitive impairment: Prevalence and predictive validity. *Psychol Med* 33: 1029-1038 (2003).
- [28] Zanetti M, Ballabio C, Abbate C, Cutaia C, Vergani C and Bergamaschini L. Mild cognitive impairment subtypes and vascular dementia in community-dwelling elderly people: a 3-year follow-up study. *J Am Geriatr Soc* 54(4): 580-586 (2006).
- [29] Perri R, Serra L, Carlesimo GA and Caltagirone C. Preclinical dementia: an Italian multicentre study on amnesic mild cognitive impairment. *Dement Geriatr Cogn Disord* 23(5): 289-300 (2007).
- [30] DeCarli C, Miller BL, Swan GE, Reed T, Wolf PA and Carmelli D. Cerebrovascular and brain morphologic correlates of mild cognitive impairment in the National Heart, Lung, and Blood Institute Twin Study. *Arch Neurol* 58(4): 643-647 (2001).
- [31] Iachini T, Sergi I, Ruggiero G and Gnisci A. Gender differences in object location memory in a real three-dimensional environment. *Brain Cogn* 59(1): 52-59 (2005).
- [32] Ruggiero G, Sergi I and Iachini S. Gender differences in remembering and inferring spatial distances. *Memory* 2008; DOI: 10.1080/09658210802307695
- [33] Eilan N. Molyneux's question and the idea of an external world. In: Eilan N, McCarthy RA and Brewer B, Eds. *Spatial representation: Problems in philosophy and psychology*. Blackwell Publishing, Malden, MA, US, pp. 236-255 (1993).
- [34] Pinker S. Visual cognition: an introduction. *Cognition* 18(1-3): 1-63 (1984).
- [35] Ungerleider LG and Mishkin M. Two cortical visual systems. In: Ingle DJ, Goodale MA and Mansfield RJW, Eds. *Analysis of visual behavior*. MIT Press, Cambridge, MA, pp. 549-586 (1982).
- [36] Kosslyn SM, Ed. *Image and brain: The resolution of the imagery debate*. Cambridge, MA, US, The MIT Press (1994).
- [37] O'Keefe J and Nadel L. *The hippocampus as a cognitive map*. Oxford, Oxford University press (1978).
- [38] Paillard J, Ed. *Brain and space*. Oxford, Oxford University Press (1991).
- [39] Roskos-Ewoldsen B, McNamara TP, Shelton AL and Carr W. Mental representations of large and small spatial layouts are orientation dependent. *J Exp Psychol Learn Mem Cogn* 24(1): 215-226 (1998).
- [40] McNamara TP, Rump B and Werner S. Egocentric and geocentric frames of reference in memory of large-scale space. *Psychon Bull Rev* 10(3): 589-595 (2003).
- [41] Mou W and McNamara TP. Intrinsic frames of reference in spatial memory. *J Exp Psychol Learn Mem Cogn* 28(1): 162-170 (2002).

- [42] Avraamides MN and Kelly JW. Multiple systems of spatial memory and action. *Cogn Process* 9(2): 93-106 (2008).
- [43] Jager G and Postma A. On the hemispheric specialization for categorical and coordinate spatial relations: a review of the current evidence. *Neuropsychologia* 41(4): 504-515 (2003).
- [44] Siegel AW and White SH. The development of spatial representations of large-scale environments. In: Reese HW, Ed. *Advances in child development and behaviour*. Academic Press, New York, pp. 37-55 (1975).
- [45] Iachini T, Ruotolo F and Ruggiero G. The effects of familiarity and gender on spatial representation of a real environment. *J Environ Psychol* 2008; DOI:10.1016/j.jenvp.2008.07.001
- [46] Milner AD and Goodale MA, Eds. *The visual brain in action*. Oxford, Oxford University Press (1995).
- [47] Burgess N, Maguire EA and O'Keefe J. The human hippocampus and spatial and episodic memory. *Neuron* 35(4): 625-641 (2002).
- [48] Morris RG and Parslow D. Neurocognitive Components of Spatial Memory. In: Allen G, Ed. *Human Spatial Memory: Remembering Where*. Lawrence Erlbaum Associates, Mahwah, NJ, pp. 217-250 (2003).
- [49] Burgess N. The hippocampus, space, and viewpoints in episodic memory. *Q J Exp Psychol A* 55: 1057-1080 (2002).
- [50] Moscovitch M, Rosenbaum S, Gilboa A, Addis DR, Westmacott R, Grady C, *et al.* Functional neuroanatomy of remote, episodic, semantic and spatial memory: a unified account based on multiple trace theory. *J Anat* 207: 36-66 (2005).
- [51] Feigenbaum JD and Morris RG. Allocentric versus egocentric spatial memory after unilateral temporal lobectomy in humans. *Neuropsychology* 18: 462-472 (2004).
- [52] Kesner RP. Behavioral analysis of the contribution of the hippocampus and parietal cortex to the processing of information: Interactions and dissociations. *Hippocampus* 10: 483-490 (2000).
- [53] Wang RF and Spelke ES. Human spatial representation: insights from animals. *Trends Cogn Sci* 6(9): 376-382 (2002).
- [54] Waller D and Hodgson E. Transient and enduring spatial representations under disorientation and self-rotation. *J Exp Psychol Learn Mem Cogn* 32(4): 867-882 (2006).
- [55] Nadel L and Hardt O. The spatial brain. *Neuropsychology* 18: 473-476 (2004).
- [56] Vallar G, Lobel E, Galati G, Berthoz A, Pizzamiglio L and Le Bihan D. A fronto-parietal system for computing the egocentric spatial frame of reference in humans. *Exp Brain Res* 124(3): 281-286 (1999).
- [57] Galati G, Lobel E, Vallar G, Berthoz A, Pizzamiglio L and Le Bihan D. The neural basis of egocentric and allocentric coding of space in humans: a functional magnetic resonance study. *Exp Brain Res* 133(2): 156-164 (2000).
- [58] Committeri G, Galati G, Paradis AL, Pizzamiglio L, Berthoz A and LeBihan D. Reference frames for spatial cognition: different brain areas are involved in viewer-, object-, and landmark-centered judgments about object location. *J Cogn Neurosci* 16(9): 1517-1535 (2004).
- [59] Zaehle T, Jordan K, Wüstenberg T, Baudewig J, Dechent P and Mast FW. The neural basis of the egocentric and allocentric spatial frame of reference. *Brain Res* 1137: 92-103 (2007).
- [60] Rosenbaum RS, Ziegler M, Winocur G, Grady CL and Moscovitch M. "I have often walked down this street before": fMRI studies on the hippocampus and other structures during mental navigation of an old environment. *Hippocampus* 14: 826-835 (2004).
- [61] Maguire EA, Burgess N, Donnett JG, Frackowiak RSJ, Frith CD and O'Keefe J. Knowing where and getting there: a human navigation network. *Science* 280: 921-924 (1998).
- [62] Gahem O, Mellet E, Crivello F, Tzourio N, Mazoyer B, Berthoz A, *et al.* Mental navigation along memorized routes activates the hippocampus, precuneus, and insula. *Neuroreport* 8: 739-744 (1997).
- [63] Trojano L, Grossi D, Linden DE, Formisano E, Goebel R, Cirillo S, *et al.* Coordinate and categorical judgements in spatial imagery. An fMRI study. *Neuropsychologia* 40(10): 1666-1674 (2002).
- [64] Trojano L, Conson M, Maffei R and Grossi D. Categorical and coordinate spatial processing in the imagery domain investigated by rTMS. *Neuropsychologia* 44(9): 1569-1574 (2006).
- [65] Iachini T, Ruggiero G, Conson M and Trojano L. Lateralization of egocentric and allocentric spatial processing after parietal brain lesions. *Brain Cogn*; in press; DOI: 10.1016/j.bandc.2008.11.001.
- [66] Tulving E. Episodic and semantic memory. In: Tulving E and Donaldson W, Eds. *Organization of memory*. Academy Press, New York (1972).
- [67] Spencer WD and Raz N. Differential effects of aging on memory for content and context: a meta-analysis. *Psychol Aging* 10(4): 527-539 (1995).
- [68] Kirasic KC. Age difference in adults' spatial abilities, learning environmental layout, and wayfinding behavior. *Spat Cogn Comput* 2: 117-134 (2000).
- [69] Salthouse TA and Mitchell DRD. Structural and operational capacities in integrative spatial ability. *Psychol Aging* 4: 18-25 (1989).
- [70] Mayr U, Kliegl R and Krampe RT. Sequential and coordinative processing dynamics in figural transformations across the life span. *Cognition* 59: 61-90 (1996).
- [71] Iachini T, Poderico C, Ruggiero G and Iavarone A. Age differences in mental scanning of locomotor maps. *Disabil Rehabil* 27: 741-752 (2005).
- [72] Iachini T, Ruggiero G, Ruotolo F and Pizza R. Age and gender differences in some components of spatial cognition. In: Benninghouse HT and Rosset AG, Eds. *Women and Aging: New Research*. Nova Science Publishers, New York (2008).
- [73] Cerella J. Age effects may be global, not local: Comment on Fisk and Rogers. *J Exp Psychol Gen* 120: 215-223 (1991).
- [74] Salthouse TA. General and specific speed mediation of adult age differences in memory. *J Gerontol B Psychol Sci Soc Sci* 51B: 30-42 (1996).
- [75] Craik FIM. A functional account of age differences in memory. In: Klix F and Hagendorf H, Eds. *Human memory and cognitive capabilities*. North-Holland, Amsterdam, pp. 409-422 (1986).
- [76] Light LL. Memory and aging: four hypotheses in search of data. *Annu Rev Psychol* 42: 333-376 (1991).
- [77] Cornoldi C and Vecchi T, Eds. *Visuo-spatial working memory and individual differences*. Hove, Psychology Press (2003).
- [78] Vecchi T and Cornoldi C. Passive storage and active manipulation in visuo-spatial working memory: Further evidence from the study of age differences. *Eur J Cognit Psychol* 11: 391-406 (1999).
- [79] Iachini T and Ruggiero G. Egocentric and allocentric spatial frames of reference: a direct measure. *Cogn Proc* 7: 126-127 (2006).
- [80] Parkin AJ, Walter BM and Hunkin NM. Relationships between normal aging, frontal lobe function, and memory for temporal and spatial information. *Neuropsychology* 9: 304-312 (1995).
- [81] Meadmore KL, Dror IE and Bucks RS. Lateralisation of spatial processing and age. *Laterality* 24: 1-13 (2008).
- [82] Sharps MJ and Gollin ES. Aging and free recall for objects located in space. *J Gerontol* 43(1): 8-11 (1988).
- [83] Cherry KE and Park DC. Individual difference and contextual variables influence spatial memory in younger and older adults. *Psychol Aging* 8(4): 517-526 (1993).
- [84] Utzl B and Graf P. Episodic spatial memory in adulthood. *Psychol Aging* 8(2): 257-273 (1993).
- [85] Cherry KE and Jones MW. Age-related differences in spatial memory: effects of structural and organizational context. *J Gen Psychol* 126(1): 53-73 (1999).
- [86] Connelly SL and Hasher L. Aging and the inhibition of spatial location. *J Exp Psychol Hum Percept Perform* 19(6): 1238-1250 (1993).
- [87] Shepard RN and Metzler J. Mental rotation of three-dimensional objects. *Science* 171(972): 701-703 (1971).
- [88] Kosslyn SM, Ball TM and Reiser BJ. Visual images preserve metric spatial information: Evidence from studies of image scanning. *J Exp Psychol Hum Percept Perform* 4(1): 47-60 (1978).
- [89] Berg C, Hertzog C and Hunt E. Age differences in the speed of mental rotation. *Dev Psychol* 18: 95-107 (1982).
- [90] De Beni R, Pazzaglia F and Gardini S. The role of mental rotation and age in spatial perspective-taking tasks: when age does not impair perspective-taking performance. *Appl Cogn Psychol* 20(6): 807-821 (2006).
- [91] Gaylord SA and Marsh GR. Age differences in the speed of a spatial cognitive process. *J Gerontol* 30(6): 674-678 (1975).
- [92] Hertzog C, Vernon MC and Rypma B. Age differences in mental rotation task performance: The influence of speed/accuracy trade-offs. *J Gerontol* 48(3): 150-156 (1993).
- [93] Craik FI and Dirks E. Age-related differences in three tests of visual imagery. *Psychol Aging* 7(4): 661-665 (1992).

- [94] Dror IE and Kosslyn SM. Mental imagery and aging. *Psychol Aging* 9(1): 90-102 (1994).
- [95] De Beni R, Pazzaglia F and Gardini S. The generation and maintenance of visual mental images: evidence from image type and aging. *Brain Cogn* 63(3): 271-278 (2007).
- [96] Palladino P and De Beni R. When mental images are very detailed: image generation and memory performance as a function of age. *Acta Psychol* 113(3): 297-314 (2003).
- [97] Brown HD, Kosslyn SM and Dror IE. Aging and scanning of imagined and perceived visual images. *Exp Aging Res* 24: 181-194 (1998).
- [98] Devlin AS, Ed. *Mind and maze: Spatial cognition and environmental behavior*. Westport, Connecticut, Praeger (2001).
- [99] Willis SL. Cognition and Everyday Competence. *Annu Rev Gerontol Geriatr* 11: 80-109 (1991).
- [100] Kirasic KC. The effects of age and environmental familiarity on adults' spatial problem-solving performance: evidence of a hometown advantage. *Exp Aging Res* 15: 181-187 (1989).
- [101] Kirasic KC, Allen GL and Haggerty D. Age-Related Differences in Adults' Macroscale Cognitive Processes. *Exp Aging Res* 18: 33-39 (1992).
- [102] Kirasic KC. Spatial cognition and behavior in young and elderly adults: implications for learning new environments. *Psychol Aging* 6(1):10-18 (1991).
- [103] Lipman PD and Caplan LJ. Adult age differences in memory for routes: effects of instruction and spatial diagram. *Psychol Aging* 7(3): 435-442 (1992).
- [104] Barrash J. Age-Related Decline in Route Learning Ability. *Dev Neuropsychol* 10: 189-201 (1994).
- [105] Wilkiss SM, Jones MG, Korol DL, Gold PE and Manning CA. Age-related differences in an ecologically based study of route learning. *Psychol Aging* 12(2): 372-375 (1997).
- [106] Moffat SD and Resnick SM. Effects of age on virtual environment place navigation and allocentric cognitive mapping. *Behav Neurosci* 116(5): 851-859 (2002).
- [107] Salthouse T and Siedlecki KL. Efficiency of route selection as a function of adult age. *Brain Cogn* 63: 279-286 (2007).
- [108] Allain P, Nicoleau S, Pinon K, Etcharry-Boux F, Barre J, Gerrut G, *et al.* Executive functioning in normal aging: a study of action planning using the Zoo Map Test. *Brain Cogn* 57: 4-7 (2005).
- [109] Newman MC and Kaszniak AW. Spatial memory and aging: performance on a human analog of the Morris water maze. *Neuropsychol Dev Cogn B Aging Neuropsychol Cogn* 7: 86-93 (2000).
- [110] Moffat SD, Kennedy KM, Rodrigue KM and Raz N. Extrahippocampal Contributions to Age Differences in Human Spatial Navigation. *Cereb Cortex* 17(6): 1274-1282 (2007).
- [111] Baudic S, Barba GD, Thibaudet MC, Smaghe A, Remy P and Traykov L. Executive function deficits in early Alzheimer's disease and their relations with episodic memory. *Arch Clin Neuropsychol* 21:15-21 (2006).
- [112] Beversdorf DQ, Ferguson JLW, Hillier A, Sharma UK, Nagaraja HN, Bornstein RA, *et al.* Problem solving ability in patients with Mild Cognitive Impairment. *Cogn Behav Neurol* 20(1): 44-47 (2007).
- [113] Buccione I, Perri R, Carlesimo GA, Fadda L, Serra L, Scalmana S, *et al.* Cognitive and behavioural predictors of progression rates in Alzheimer's disease. *Eur J Neurol* 14: 440-446 (2007).
- [114] dePolvi AR, Rankin KP, Mucke L, Miller BL and Gorno-Tempini ML. Spatial cognition and the human navigation network in AD and MCI. *Neurology* 69(10): 986-997 (2007).
- [115] Kasai M, Meguro K, Hashimoto R, Ishizaki J, Yamadori A and Mori E. Non-verbal learning is impaired in very mild Alzheimer's disease (CDR 0.5): normative data from the learning version of the Rey-Osterrieth Complex Figure Test. *Psychiatry Clin Neurosci* 60(2): 139-146 (2006).
- [116] Wechsler D. *WAIS-R manual*. San Antonio, TX, The Psychological Corporation (1981).
- [117] Strite D, Massman PJ, Cooke N and Doody RS. Neuropsychological asymmetry in Alzheimer's disease: Verbal versus visuoconstructional deficits across stages of dementia. *J Int Neuropsychol Soc* 3: 420-427 (1997).
- [118] Raven JC. *Guide to using the coloured progressive matrices*. London (1965).
- [119] Franceschi M, Caffarra P, De Vreese L, Pelati O, Pradelli S, Savarè R, *et al.* Visuospatial planning and problem solving in Alzheimer's disease patients: a study with the Tower of London Test. *Dement Geriatr Cogn Disord* 24(6): 424-428 (2007).
- [120] Hashimoto R, Meguro K, Lee E, Kasai M, Ishii H and Yamaguchi S. Effect of age and education on the Trail Making Test and determination of normative data for Japanese elderly people: The Tajiri Project. *Psychiatr Clin Neurosci* 60: 422-428 (2006).
- [121] Saumier D, Murtha S, Bergman H, Phillips N, Whitehead V and Chertkow H. Cognitive predictors of donepezil therapy response in Alzheimer disease. *Dement Geriatr Cogn Disord* 24(1): 28-35 (2007).
- [122] Benton AL, Hamsher K, Varney HR and Spreen O. *Contributions to neuropsychological assessment: A clinical manual*. New York, Oxford University Press (1983).
- [123] Caine D and Hodges JR. Heterogeneity of semantic and visuospatial deficits in early Alzheimer's disease. *Neuropsychology* 15(2): 155-164 (2001).
- [124] Money J. *A Standardized road map test of direction sense*. San Rafael, CA, Academic Therapy Publications (1976).
- [125] Mapstone M, Steffenella TM and Duffy CJ. A visuospatial variant of mild cognitive impairment: getting lost between aging and AD. *Neurology* 60(5): 802-808 (2003).
- [126] Kavcic V, Fernandez R, Logan D and Duffy CJ. Neurophysiological and perceptual correlates of navigational impairment in Alzheimer's disease. *Brain* 129: 736-746 (2006).
- [127] Milner B. Interhemispheric differences in the localization of psychological processes in man. *Br Med Bull* 27: 272-277 (1971).
- [128] Della Sala S, Gray C, Baddeley A, Allamano N and Wilson L. Pattern span: a tool for unwelcoming visuo-spatial memory. *Neuropsychologia* 37(10): 1189-1199 (1999).
- [129] Becker JT, Huff J, Nebes RD, Holland A and Boiler F. Neuropsychological function in Alzheimer's disease: Pattern of impairment and rates of progression. *Arch Neurol* 45: 263-268 (1988).
- [130] Galton CJ, Patterson K, Xuereb JH and Hodges JR. Atypical and typical presentations of Alzheimer's disease: A clinical neuropsychological, neuroimaging and pathological study of 13 cases. *Brain* 123: 484-498 (2000).
- [131] Martin A. Neuropsychology of Alzheimer's disease: The case for subgroups. In: Schwartz MF, Ed. *Modular deficits in Alzheimer-type disease*. The MIT Press, Cambridge, MA, pp. 143-175 (1990).
- [132] Kaskie B and Storandt M. Visuospatial deficit in dementia of the Alzheimer type. *Arch Neurol* 52: 422-425 (1995).
- [133] Kurylo DD, Corkin S and Rizzo JF. Greater relative impairment of object recognition than of visuospatial abilities in Alzheimer's disease. *Neuropsychology* 10: 74-81 (1996).
- [134] Nordlund A, Rolstad S, Hellström P, Sjögren M, Hansen S and Wallin A. The Goteborg MCI study: mild cognitive impairment is a heterogeneous condition. *J Neurol Neurosurg Psychiatry* 76(11): 1485-1490 (2005).
- [135] Pai MC and Jacobs WJ. Topographical disorientation in community-residing patients with Alzheimer's disease. *Int J Geriatr Psychiatry* 19(3): 250-255 (2004).
- [136] O'Brien HL, Tetewsky SJ, Avery LM, Cushman LA, Makous W and Duffy CJ. Visual mechanisms of spatial disorientation in Alzheimer's disease. *Cereb Cortex* 11(11): 1083-1092 (2001).
- [137] Rizzo M, Anderson SW, Dawson J, Myers R and Ball K. Visual attention impairments in Alzheimer's disease. *Neurology* 54: 1954-1959 (2000).
- [138] Fujimori M, Imamura T, Hirono N, Ishii K, Sasaki M and Moria E. Disturbances of spatial vision and object vision correlate differently with regional cerebral glucose metabolism in Alzheimer's disease. *Neuropsychologia* 38: 1356-1361 (2000).
- [139] Vannini P, Almkvist O, Dierks T, Lehmann C and Wahlund LO. Reduced neuronal efficacy in progressive mild cognitive impairment: a prospective fMRI study on visuospatial processing. *Psychiatr Res* 156(1): 43-57 (2007).
- [140] Rey A. *L'Examen Clinique en Psychologie*. Paris, Presses Universitaires de France (1959).
- [141] Reitan RM. Validity of the trail-making tests as an indication of organic brain damage. *Percept Mot Skills* 8: 271-276 (1958).
- [142] Adelstein TB, Kesner KP, Strassberg DS. Spatial recognition and spatial order memory in patients with dementia of the Alzheimer's type. *Neuropsychologia* 30: 59-67 (1992).
- [143] Sahakian BJ, Morris RG, Evenden JL, Heald A, Levy R, Philpot M, *et al.* A comparative study of visuospatial memory and learning



- in Alzheimer-type dementia and Parkinson's disease. *Brain* 111: 695-718 (1988).
- [144] Bucks RS and Willison JR. Development and validation of the Location Learning Test (LLT): a test of visuo-spatial learning designed for use with older adults and in dementia. *Clin Neuropsychologist* 11: 273-286 (1997).
- [145] Vecchi T, Saveriano V and Paciaroni L. Storage and processing working memory functions in Alzheimer-type dementia. *Behav Neurol* 11: 227-231 (1998).
- [146] Lineweaver TT, Salmon DP, Bondi MW and Corey-Bloom J. Differential effects of Alzheimer's disease and Huntington's disease on the performance of mental rotation. *J Int Neuropsychol Soc* 11(1): 30-39 (2005).
- [147] Toepper M, Beblo T, Thomas C and Driessen M. Early detection of Alzheimer's disease: a new working memory paradigm. *Int J Geriatr Psychiatry* 23(3): 272-278 (2008).
- [148] Kessels RP, Feijen J and Postma A. Implicit and explicit memory for spatial information in Alzheimer's disease. *Dement Geriatr Cogn Disord* 20: 184-191 (2005).
- [149] Troyer AK, Murphy KJ, Anderson ND, Hayman-Abello BA, Craik FI and Moscovitch M. Item and associative memory in amnesic mild cognitive impairment: performance on standardized memory tests. *Neuropsychology* 22(1): 10-16 (2008).
- [150] Apostolova LG and Thompson PM. Mapping progressive brain structural changes in early Alzheimer's disease and mild cognitive impairment. *Neuropsychologia* 46(6): 1597-1612 (2008).
- [151] Blennow K. Cerebrospinal fluid protein biomarkers for Alzheimer's disease. *NeuroRx* 1(2): 213-225 (2004).
- [152] Delacourte A, David JP, Sergeant N, Buée L, Wattez A, Vermersch P, *et al.* The biochemical pathway of neurofibrillary degeneration in aging and Alzheimer's disease. *Neurology* 52(6): 1158-1165 (1999).
- [153] Killiany RJ, Gomez-Isla T, Moss M, Kikinis R, Sandor T, Jolesz F, *et al.* Use of structural magnetic resonance imaging to predict who will get Alzheimer's disease. *Ann Neurol* 47: 430-439 (2000).
- [154] Thompson PM, Hayashi KM, de Zubicaray G, Janke AL, Rose SE, Semple J, *et al.* Dynamics of gray matter loss in Alzheimer's disease. *J Neurosci* 23(3): 994-1005 (2003).
- [155] Jelic V and Nordberg A. Early diagnosis of Alzheimer's disease with positron emission tomography. *Alzheimer Dis Assoc Disord* 14: S109-S113 (2000).
- [156] Arnaiz E, Blomberg M, Fernaeus SE, Wahlund LO, Winblad B and Almkvist O. Psychometric discrimination of Alzheimer's disease and mild cognitive impairment. *Alzheimers Rep* 3: 97-104 (2000).
- [157] Prvulovic D, Hubl D, Sack AT, Melillo L, Maurer K, Frolich L, *et al.* Functional imaging of visuospatial processing in Alzheimer's disease. *NeuroImage* 17: 1403-1414 (2000).
- [158] Foster NL, Chase TN, Fedio P, Patronas NJ, Brooks RA and Di Chiro G. Alzheimer's disease: focal cortical changes shown by positron emission tomography. *Neurology* 33: 961-965 (1983).
- [159] Ober BA, Jagust WJ, Koss E, Delis DC and Friedland RP. Visuoconstructive performance and regional cerebral glucose metabolism in Alzheimer's disease. *J Clin Exp Neuropsychol* 13: 752-772 (1991).
- [160] Pietrini P, Furey ML, Graff-Radford N, Fieo U, Alexander GE, Grady CL, *et al.* Preferential metabolic involvement of visual cortical areas in a subtype of Alzheimer's disease: clinical implications. *Am J Psychiatry* 153: 1261-1268 (1996).

---

Received: October 10, 2008

Revised: November 05, 2008

Accepted: November 13, 2008